

High Functioning Autism; A Case Study

History.

At the age of 20 months, this patient had difficulty speaking, obsessive behaviours, regular mood swings and poor social behaviour. He was born 10 days overdue with a multiple instrument-assisted birth. Until the age of 18-20 months, he developed normally and met all milestones as expected. He was also given the full spectrum of standard immunisations until the age of 18 months, including MMR and chickenpox. At the age of 18 months he lost eye contact, he began rocking back and forth, developed obsessive behaviours, had regular mood swings and tantrums, and did not develop his speech. These symptoms did not progress and were consistent. Upon presentation, this patient's only method of communication was by sounds, he constantly ran to the nearest door and repeatedly opened and closed it sometimes locking himself in. He had no interaction with other people in the room including eye contact, no acknowledgement that he had been spoken to, no comprehension of what was said to him, and no emotional interaction. He constantly ran aimlessly up and down the corridor and was unable to be toilet trained despite multiple attempts.

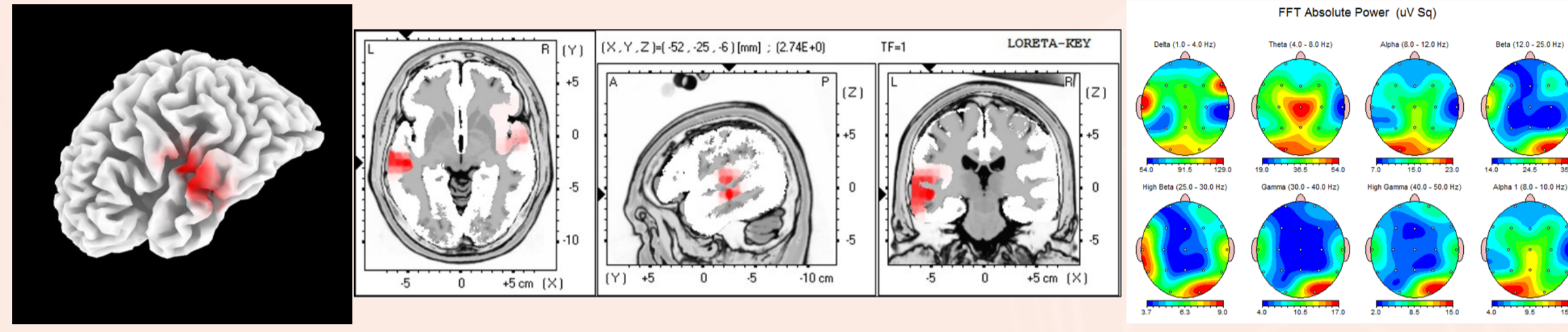
Physical Exam

Physical examination demonstrated dysmetria in the left finger-to-nose test, dysmetric optokinetic testing bilaterally and reduced (1+) deep tendon reflexes of the upper and lower limb on the right side. All other testing, including an upper and lower limb neurological exam as well as a cranial nerve exam, were within normal limits.

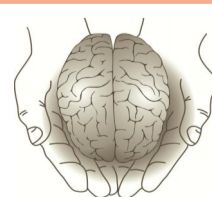
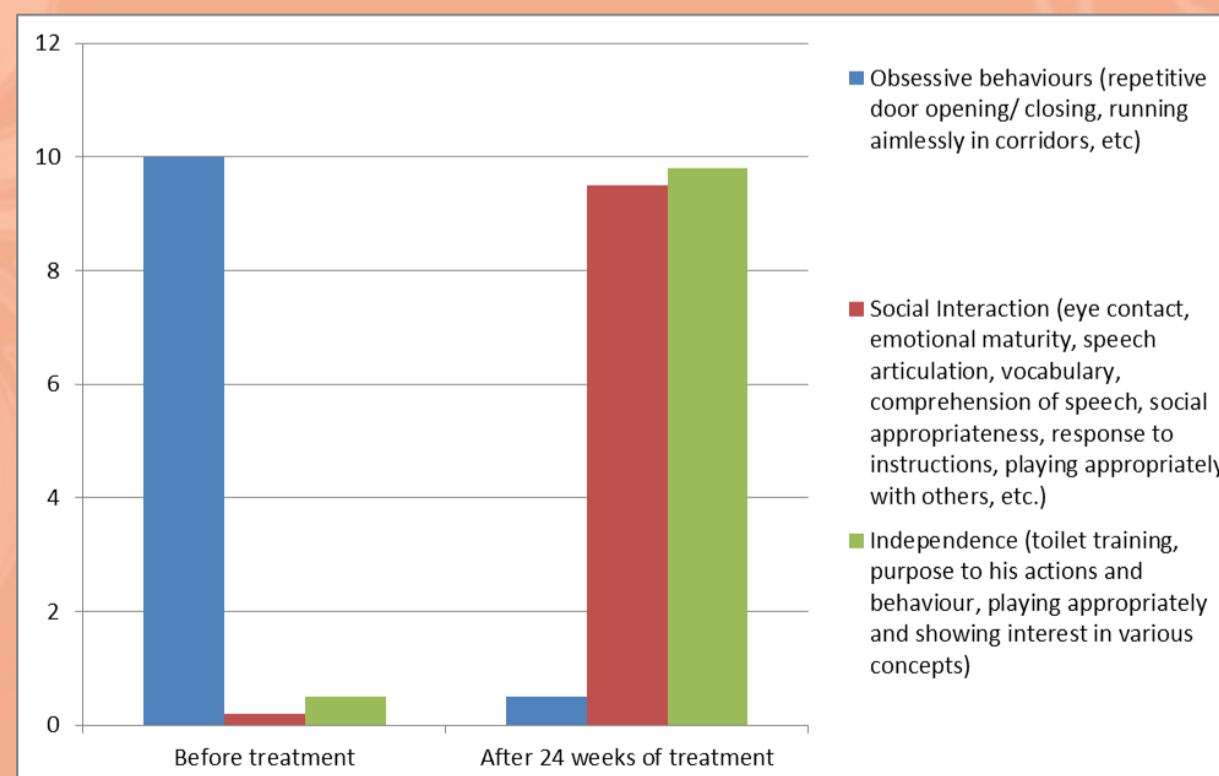
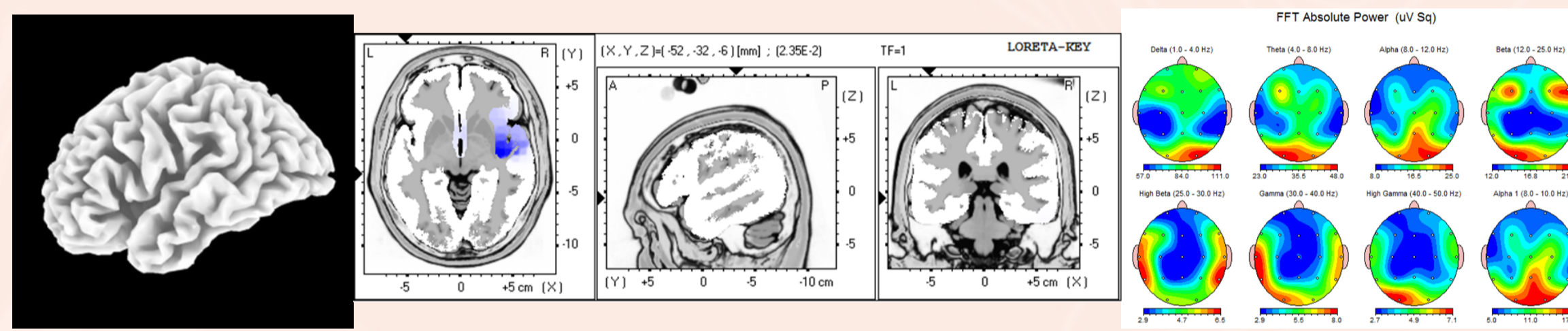
Initial Findings:

Upon initial quantitative electroencephalography (qEEG) there was a significant decrease in function over the frontal cortex as well as the midline frontal cortex bilaterally. This seemed to be more prominent in

Initial Findings



Final Findings



Institute of
Functional Neuroscience

Dr Francesca Buhagiar BSc., BChiro(Dist.), DACNB., FAAFN

the left frontal region and therefore this became the focus of treatment initially. His coherence was also dysfunctional mainly in the left frontal and parietal regions. Low resolution electromagnetic tomography (LORETA) analysis showed that the most significant dysfunction was in Brodmann area 21 which is in the left language area of the brain. It is involved in selective processing of text and speech, semantic processing, sentence generation, word generation, visual observation of motion, auditory processing of complex sounds, attribution of intentions and deductive reasoning.

Report Findings

The follow up qEEG examination demonstrated a normalization of the hypoactivity in the frontal lobes within the delta, theta, alpha and beta frequencies. There is a residual central frontal / cingulate gyrus hypoactivation which will

continue to be treated to achieve normalization. LORETA analysis showed that the area of dysfunction (Brodmann area 21) was completely normalized and no dysfunction was present.

Conclusion

After a few months of therapy, the qEEG had improved significantly in appearance showing normalization of the hypoactive areas in some frequency ranges. LORETA analysis demonstrated complete resolution of the primary dysfunctional area. Symptomatically, the patient's parents report an increase in function in every aspect of their child's life. He is now fully toilet trained and interacts verbally and emotionally with those around him in an appropriate manner. He uses a full range of vocabulary and is interested in his surroundings. Comprehension of all conversation is age appropriate and he responds adequately and in a timely manner. His obsessive behaviours are reduced to age appropriate 'airplane fascination', there are no signs of running around or repeated door closing/opening. He is well behaved, can interact better at school and is a pleasure to be around. To the new acquaintance, he does not show autistic traits or behavioural dysfunction.